

Cysticercosis of Breast - A Rare Entity

Abhijeet Ingle¹, Vijaya Gattu ², Suhela Rachakonda³, Sai babu⁴, Anamika Aluri⁵

¹ Consultant Histopathologist

² Consultant Pathologist

³ Consultant Pathologist

⁴ Consultant Surgeon

⁵ Consultant Biochemist &

Head Biochemistry lab.

Yashoda Hospital

Malakpet

Nalgonda X- Roads,

Hyderabad – 500 036.

CORRESPONDENCE :

¹ Dr. Abhijeet Ingle, MD

Consultant Histopathologist

Yashoda Hospital

Malakpet

Nalgonda X- Roads

Hyderabad – 500 036.

E-mail: suhela24@gmail.com

ABSTRACT

It is unusual for cysticercosis to occur in the substance of the breast. Diagnosis is usually made incidentally. Only few cases are described in the literature. We here report a case of cysticercosis perched on fibrocystic disease of breast found on surgical excision in a 36-year-old female patient.

The patient had no discernible evidence of cysticercosis in the other organs. Surgical excision was performed and histological examination demonstrated the presence of cysticercus cellulosae larvae. Characteristic features of this uncommon location are discussed based on a review of the literature. Thus the possibility of cysticercosis of the breast should be kept in mind while considering the differential diagnosis for a breast lump.

Keywords : Breast, cysticercosis, pigs, scolex, taenia solium, taeniasis.

INTRODUCTION

Cysticercosis is caused by the systemic dissemination of the larval form of the pork tapeworm, *Tenia solium* (TS). Developing countries show a high prevalence of the infection due to coexistence of poor sanitary conditions and domestic pig raising without veterinary control or surveillance systems.^[1] It is common in developing countries like China, India, Chile, Brazil, Papua, Southern Africa, Central America, New Guinea, and non-Islamic South-East Asia where pigs feed on human faeces and where undercooked or raw pork is consumed.

Humans are usually infected by eating raw or undercooked pork that has been infected with larvae (cysticerci). Pigs ingest eggs in human faeces, and the eggs are then lysed in the gut by gastric juice. Oncospheres hatch, invade the intestinal wall, and reach the bloodstream. The oncospheres then spread to the central nervous system, skeletal muscle, subcutaneous tissue, eyes, breast, and heart, where they develop into cysticerci.^[2]

When humans ingest raw or undercooked infected meat,

enzymes lyse the outer shell of the parasite leaving the scolex behind. The scolex has suckers and hooks that aid in attachment to the intestinal wall. Once the parasite has attached itself to the intestinal wall, the scolex proliferates and becomes an adult tapeworm over two months and can survive for years within the human intestines. Adult tapeworms produce eggs (proglottidis) that mature, become gravid, detach from tapeworm, and migrate to the anus or are passed in the stool. When pigs ingest the eggs from infected soil, the cycle begins again.^[3]

Although central nervous system involvement constitutes the primary site of infection, other organs, including the breast, can be involved. Because these parasites are seen as lumps in the breast, they are cause for concern because they are often clinically suspected to be malignant. We here report a patient with cysticercosis of the breast.

CASE REPORT

A 36-year-old female, admitted to Surgery Department at Yashoda Hospital (Malakpet) with complaint of lump in the left breast. The patient was clinically examined and found to have approximately 2cm x 1.5cm mass in the

lower outer quadrant. Mammography, ultrasound and CECT were not performed.

Routine investigations showed haemoglobin (Hb) 11.9 g/dL, the total leucocyte count (TLC) was 9400/cu. mm, the differential leucocyte count- neutrophils (61%), lymphocytes(35%), eosinophils (02%) and monocytes (02%). Biochemical parameters were unremarkable. Urine examination was normal. Under local anaesthesia excision of the lump was done.

On sectioning the left breast mass, a grey white solid and cystic area seen measuring approximately 1.4 X 1.2X1 cm in diameter .

Histopathological examination revealed fibrocollagenous cyst without lining and foci of necrosis.

Cyst wall and adjacent breast parenchyma shows dense mixed inflammatory infiltrate including eosinophils .Also identified were the remains of the cysticercus cellulose larvae. Thus, the histopathological features confirmed the diagnosis of cysticercosis. (Figure 1 ,2 ,3 & 4).

DISCUSSION

Cysticercosis is due to the tissue infestation with the larval forms of *T. Solium*. It spreads via faeco oral route because of greater contact of human beings with pigs and is thus more common in developing countries, namely, Latin America, Southern Africa, India, Southeast Asia and Eastern Europe where there is fecal contamination of food and water due to overcrowding of society and poor sanitation. ^[4,5,6,7]

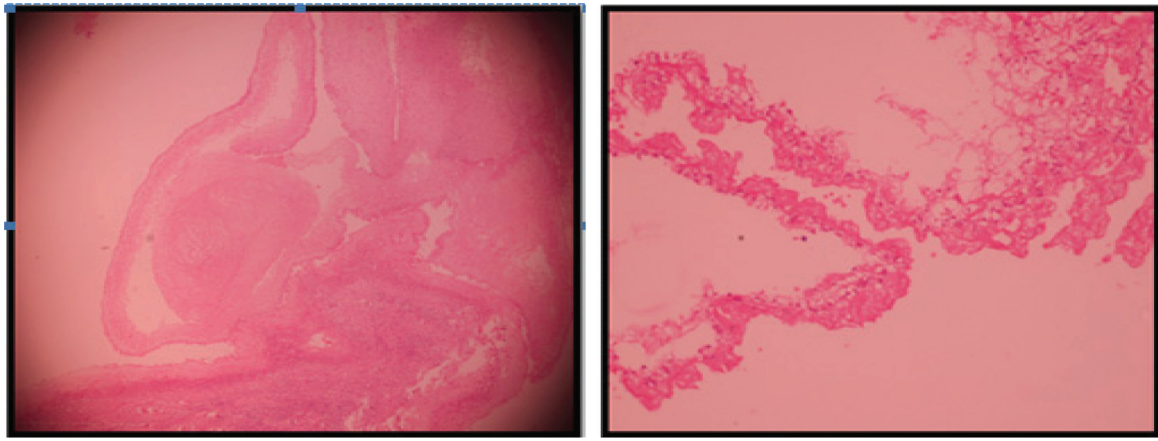


Figure 1 & 2 : Hematoxylin and eosin stained histopathology image showing cysticercus cellulose cyst wall

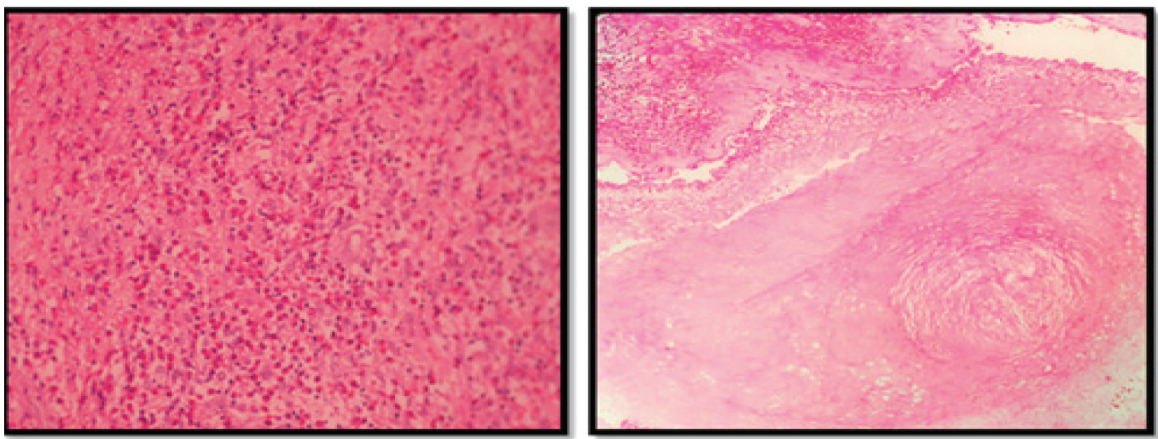


Figure 3 & 4 : Hematoxylin and eosin stained histopathology image showing cysticercus with eosinophils and inflammatory reaction

The clinical manifestations of *T. Solium* are variable, i.e. Taeniasis where humans are being infected with adult tapeworms in the intestine or cysticercosis where the larval forms exist in the tissues. However, both the forms of infection can co exist in the same patient. The only definitive hosts are human beings whereas pigs are the usual intermediate hosts. Other animals like dogs, cats, and sheep may also act as intermediate hosts. On reaching the GIT of the intermediate host these eggs rupture and oncospheres are liberated which penetrate the gut wall and via the systemic circulation are lodged in different organs and muscles where, they develop into larvae referred to as cysticercosis cellulosae especially in subcutaneous tissue; striated muscles, brain and ocular tissue.^[6,7,8] Humans are infected through eating undercooked contaminated pork, where it develops into the adult tapeworm in the jejunum. Autoinfection may also be seen by reverse intestinal peristaltic movement or by finger contamination due to non washing of hands.

The growing larva in cysticercosis may provoke a series of inflammatory reactions including infiltration of neutrophils, eosinophils, lymphocytes, plasma cells, and at times giant cells, followed by fibrosis and necrosis with eventual calcification of the larva. Cysticerci as long as they live do not elicit immune response; however, following death of larvae, a strong acute inflammatory response may be triggered due to leakage of fluid from the cysts.^[5,6]

Earlier a case report of cysticercosis of anterior abdominal wall musculature was reported by Mani et al.^[9] which was diagnosed ultrasonographically as a solitary cysticercal cyst. The ultrasound report revealed a well-defined cystic lesion. It had an eccentric, echogenic, pedunculated structure without any calcification protruding within the cystic area. There was associated inflammation and hypervascularity in the surrounding muscle.

Oral mucosa is a rare site for cysticercosis. Mazhari et al.^[10] described eight cases of cysticercosis involving the oral cavity. All of them presented with a solitary superficial mucosal nodule, of these four were in the buccal mucosa, two in the lips, one in the tongue and one in the gums.

Breast cysticercosis is difficult to diagnose. A history of residence or travel in a parasite endemic area or the presence of infected animals in a patient's environment is sometimes helpful.

Magnetic resonance imaging and computed tomography are useful in detecting and evaluating specific stages of cysticercosis. Initially, when the parasite is viable, a cyst without peripheral enhancement is seen. Peripherally enhancing cystic lesions are subsequently observed, which indicates the inflammatory response that occurs

after the death of the parasite.

Thus although, cysticercosis of the breast is an extremely rare entity, it should always be kept at the back of mind while considering the differential diagnosis for a benign lump in the breast.

Definitive diagnosis of soft tissue cysticercosis can be confirmed by excisional surgery or by needle or open biopsy.

CONCLUSION

Although cysticercosis presents as a lump in various sites of the human body like skeletal muscle, CNS and subcutaneous tissue, but is an extremely rare disease entity to clinically present as breast lump, but it should be always be kept in mind when other causes of breast lump have been excluded.

CONFLICT OF INTEREST :

The authors declared no conflict of interest.

FUNDING : None

REFERENCES

1. García HH, Gilman RH, Gonzalez AE, et al. Hyperendemic human and porcine *Taenia solium* infection in Perú. *Am J Trop Med Hyg.* 2003; 68: 268-75.
2. King CH. *Cestode infections.* Goldman L, Ausiello D, eds. *Cecil Textbook of Medicine.* 22nd edition. Volume 2. Philadelphia: Elsevier, 2004: 2460-2461.
3. Ergen FB, Turkbey B, Kerimoglu U, Karaman K, Yorganc K, Saglam A. Solitary cysticercosis in the intermuscular area of thigh: a rare and unusual pseudotumor with characteristic imaging findings. *J Comput Assist Tomogr.* 2005; 29:260-263.
4. Gupta SC, Gupta SC. Cysticercosis of the tongue. *Ear Nose Throat J.* 1995; 74; 174:177-178.
5. Saran RK, Rattan V, Rajwansi A, Nijkawan R, Gupta SK. Cysticercosis of the oral cavity: report of five cases and a review of literature. *Int J Paediatr Dent.* 1998; 8:273-8.
6. Gadbail AR, Korde S, Wadhwan V, Chaudhary M, Patil S. Oral cysticercosis: report of two cases with review of literature. *Oral Surgery.* 2010; 3:51-56.
7. Jain RK, Gupta OP, Aryya NC. Cysticercosis of the tongue. *J Laryngol Otol.* 1989; 103:1227.
8. Pandey SC, Pandey SD. Lingual cysticercosis. *Indian J Plast Surg.* 2005; 38:160-161.
9. Mani NB, Kalra N, Jain M, Sidhu R. Sonographic diagnosis of a solitary intramuscular cysticercal cyst. *J Clin Ultrasound.* 2001; 29:472-475.
10. Mazhari NJ, Kumar N, Jain S. Cysticercosis of the oral mucosa: aspiration cytologic diagnosis. *J Oral Pathol Med.* 2001; 30:187-189.